



The study of the broiler chickens' growth by X-ray computerized tomography

**G. Andrásy-Baka, R. Romvári, Z. Sütő, J. Csapó,
A. Szabó, L. Locsmáncsi**

University of Kaposvár, Faculty of Animal Science, Kaposvár, H-7400 Guba Sándor u. 40.

ABSTRACT

Non-invasive computerized tomography was performed on commercial broiler chickens, in both sexes, between 4 to 18 weeks of age, to determine the growth rate of tissues. On the basis of 16-32 scans gathered from each bird during the scanning procedure the volumetric measurement of the breast muscle was performed. These values were the 259, 493, 786 cm³ and 195, 460, 668 cm³ in male and female birds at the age of 6, 12 and 18 weeks, respectively. The total body fat content was characterized by the so called „fat index”, a value independent of the live weight. This indices were 7.3, 7.14, 9.48 and 8.8, 13.3, 21.6 following the above order. Total body fat content was determined both by CT and chemical analysis. The investigation of the tissue development in the body was carried out by means of 3D histograms, which shows the tissue composition of chicken bodies, with different peaks corresponding to the breast, drumstick and thighs muscles. Fat depots were also definitely showed, with different peaks in the neck- and abdominal regions. The volume and the anatomical location of both fat and muscle tissue were determined.

(Keywords: broiler chickens, growth, computerized tomography)

ÖSSZEFOGLALÁS

Brojlerek növekedésének vizsgálata computer tomográffal

Andrásy-Baka G., Romvári R., Sütő Z., Csapó J.,

Szabó A., Locsmáncsi L.

Kaposvári Egyetem, Állattudományi Kar, Kaposvár, H-7400 Guba Sándor u. 40.

Kereskedelmi forgalmazású brojler állomány nem invazív CT felvételezésére került sor 4-18 hetes kor között, mindkét ivarban, az izom és zsírszövet növekedési jellemzőinek vizsgálata céljából. A mellizomzat térfogatát egyedenként 16-32 CT felvétel alapján becsülve a következő értékeket kaptuk: 259, 493, 786 cm³, 195, 460, 668 cm³ hím és nőivarban 6, 12 valamint 18 hetes korban. A teljes test zsírtartalmát a testsúlytól függetlenül ún. „zsír index”-el jellemeztük. Az index értékek 7.3, 7.14, 9.48 valamint 8.8, 13.3, 21.6; voltak a két ivarban és a három életkorban. A CT-vel becsült test zsírtartalom és a kémiai analízis során nyert adatok között $R^2=0.895$ összefüggést találtunk. Az egyes szövetek térfogat változását, valamint anatómiai lokalizációját 3D hisztogramokkal követtük nyomon, különös tekintettel az izomszövetre a mell- és a comb régióban, valamint a zsírszövetre az abdominális és a nyaki tájékon az életkor és az ivar összefüggésében.

(Kulcsszavak: brojler, növekedés, computer tomográf)

INTRODUCTION

Remarkable changes have taken place in body conformation and composition of meat-type chickens in the past 50 years. While in 1950 a 12 weeks period was required to reach the slaughter weight of 1.8–2.0 kg, nowadays it takes less than the half of it. According to *Havenstein et al.* (2002), the effects of both genetics and nutrition resulted in a body weight increase of approximately 31 to 99 g/yr at 42 and 84 days, respectively, during the last decade. However, the performance limitations are unknown, though prognosis is available (*Savory*, 2002). On the other hand, parallel with the well known reduction of market age, only a few data is available for broilers raised far over normal broiler or roaster age. The *Ross 1*. broiler strain was examined until 364 days of age by *Grey et al.* (1982). The growth and chemical composition of experimental lines was studied by *Sørensen and Ducro* (1995). *Hancock et al.* (1995) characterized the growth rate of commercial genotypes until 26 weeks of age by Gompertz growth equations.

When studying the composition of growing chickens, it is often necessary to measure whole body composition. However, there is a lack of information in the literature, possibly due to the difficulties of adequate body homogenization. In reports on the a long term (20 week) fattening trial of broiler chickens (*Horn et al.*, and *Sütő et al.*, 1998), the carcass traits, abdominal fat deposition and chemical composition were studied.

In the current study parallel with the above-mentioned examinations *in vivo* CT imaging procedure was applied. Similar methods were used by *Bentse and Sehested* (1989) and *Svihus and Katle* (1993) and *Romvári et al.* (1994) for the determination of the abdominal fat amount and the breast muscle weight of broiler chickens. In regard of breast muscles comparative HRCT investigation of different broiler genotypes was performed and also complemented with 3D reconstruction by *Romvári et al.* (2000). Dual X-ray absorptiometry was applied by *Mitchell et al.* (1998) for the body composition analysis of growing broiler chickens.

MATERIALS AND METHODS

Animals

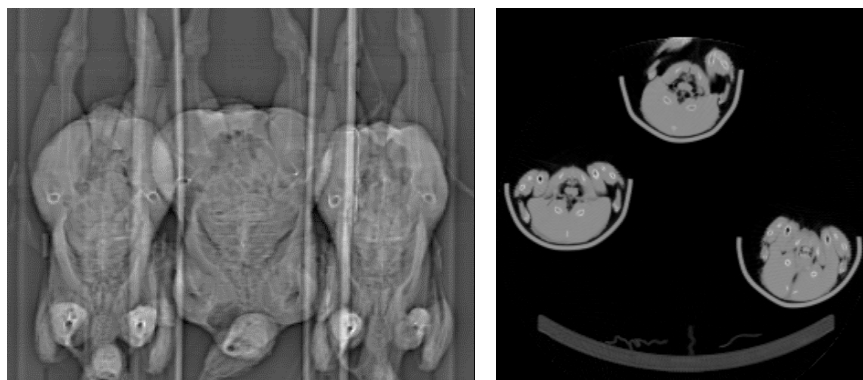
A total of 144 Arbor Acres Regular meat-type chickens were used. All birds selected for CT examination each time had to be within a 3% range deviation from the live weight mean of the population; sexes were treated separately. Six birds by sex were taken for scanning at the age 4, 5, 6, 7, 8, 9, 10, 12, 14, 16, and 18 weeks. Birds were raised in a closed, air-conditioned building on deep litter at the Test Station of the University of Kaposvár, Faculty of Animal Science. The managemental procedures applied during the 20 week growing period was described in detail by *Horn et al.* (1997).

CT procedure and data processing

The CT images were taken by means of a Siemens Somatom DRG scanner of the Institute of Diagnostic Imaging and Radiation Oncology, after 8 hours of feed withdrawal. Chickens, three at the same time, were fixed in stretched position with belts, in a specially designed holder, without using anaesthetic. The examinations started with the taking up an overall topogram, which is similar to a conventional two dimensional X-ray picture. In the topogram the anatomical locations of the cross-sectional scans or body intervals can be marked. Depending on the size of the birds 16 to 32 overlapping scans of 8 mm scan thickness were taken, covering the whole body (*Figure 1*). To equalize the size difference and to reduce the amount of raw data, altogether 16 identical anatomic locations (IAL) were chosen.

Figure 1

Two dimensional topogram of three birds and the cross-sectional image made at the anatomical point at the end of the clavicle



1. ábra: Három madárról készült kétdimenziós topogram és a klavicula végét metsző anatómiai síkban készült keresztmetszeti CT felvétel

The picture-forming pixels of CT images are in fact small prisms with defined volume. It is possible, therefore, to determine the part of the total volume of the examined scan that falls into the Hounsfield unit (HU) interval of interest. On this basis the estimation of fat tissue volume of the body was possible, from the serial scans. Pixel density data were collected from by excluding the extreme density values (corresponding to bone or air); only those corresponding to muscle and fat were retained, i.e. the range from -200 to 200 on the Hounsfield scale (fluid water=0). Each consecutive 10 HU values were summarized, resulting altogether in 40 Hounsfield variables (HUv).

Slaughtering and chemical analysis

The birds were slaughtered following a 12-hour fasting period. The breast muscle was weighed and after removal of the alimentary tract content, the rest of the broiler (empty body) was homogenized and used for chemical analysis, according to *Sütő et al.* (1998). Dry matter (DM) was determined by drying the sample at 105°C to constant weight. Crude fat (CF) was weighed after ether extraction. Hydrochloride acid digestion and Kjeld-Foss Fast Nitrogen Analyzer was used for the determination of the nitrogen content, which was converted to crude protein (CP) by multiplying with 6.25.

Statistical methods

The data arising from the sixteen intervals (representing IAL) were used for the graphical demonstration of the body composition. Based on the 40 Hounsfield variables 3D histograms were developed with negative exponential interpolation - at the age of 6, 12 and 18 weeks, in both sexes - to characterize the fat and muscle tissue development inside the body.

In order to examine the fat content of the chickens in different ages, "fat indices" were created from all the CT images, by relating pixels corresponding to fat densities to the total number of pixels according to the formula: $(HUv6-12 / HUv1-40) \times 100$ (*Romvári*, 1998). To test the predictive value of these indices, regression analysis was performed between the fat indices and the chemically determined fat content (CF) of the

body. To characterize the relative building in of the fat and muscle tissues linear and exponential regression models were developed (SPSS for Windows 10, 1999).

RESULTS AND DISCUSSION

Table 1 presents the data of chemical composition, slaughtering and CT processing originated from the three distinguished measuring points.

Table 1

**Characteristics live weight, tissue- and chemical composition data
(n=6 per sex and age)**

Males (1)	Weeks (2)					
	6		12		18	
	Mean (3)	SD (4)	Mean	SD	Mean	SD
Liveweight (5) (g)	1741	41.2	3473	65.3	5216	121.1
Abdominal Fat (6) (g)	15.7	5.47	37.2	12.4	112	38.1
Crude Fat (7) (%)	10.3	2.24	12.7	2.38	15.2	1.02
Fat Index (8)	0.07	0.01	0.07	0.01	0.09	0.02
Breast Volume (9) (cm³)	259	16.3	493	18.1	786	121
Females (10)						
Liveweight (5) (g)	1458	42.2	2933	64.1	4096	95.0
Abdominal Fat (6) (g)	18.3	4.08	51.5	41.9	235	58.6
Crude Fat (7) (%)	11.9	1.52	20.2	3.06	27.8	4.73
Fat Index (8)	0.08	0.01	0.13	0.02	0.21	0.04
Breast Volume (9) (cm³)	195	11.9	460	25.0	668	48.9

1. táblázat: Az élő súly, a szöveti valamint a kémiai összetétel jellemzői (ivaronként és koronként n=6)

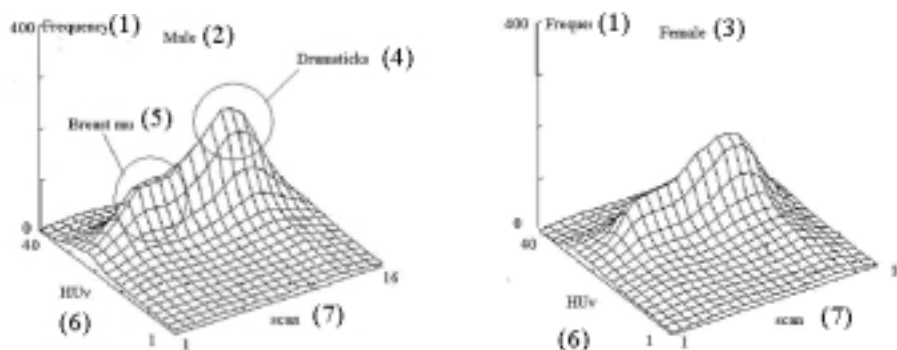
Hímivar(1), Élethét(2), Átlag(3), Szórás(4), Élő súly (g)(5), Abdominális zsír (g)(6), Nyerszsír(%) (7), Zsírindex(8), Melltér fogat(9), Nőivar(10)

Crude fat content increased from 10 to 15% in males while this change was much more pronounced in females (12-28%). The breast muscle development increased continuously in both sexes with a decreasing intensity. The breast muscle volume was larger in males than in females at all the examined live ages.

The changes of tissue composition were depicted at the age of 6, 12 and 18 weeks of age in both sexes. The 3D histograms on Figure 2, constructed from the average data of the chicken groups at the age of 6 weeks. The serial number of the pictures was illustrated on the X-axis, the HU variables on the Y-axis (numbering from 40 to 1 after reducing by 10 from +200 to -200) and the frequency of the density values on the Z-axis. For the comparability of the histograms prepared at different ages identical scaling was used. In case of 6-week-old animals, in the protrusion formed by the muscle tissue interval (HUv 21-40) two characteristic peaks are clearly to be recognized. The first from the head is the peripheral region of the breast muscle (2-6). The next, something lower part is the pelvic interval, after which the highest "peak", formed by the drumsticks and the thighs can be seen (9-15). The thigh musculature of males highly exceeded that of females at the age of 6 weeks.

Figure 2

3D histograms at the age of 6 weeks of the male and female chickens



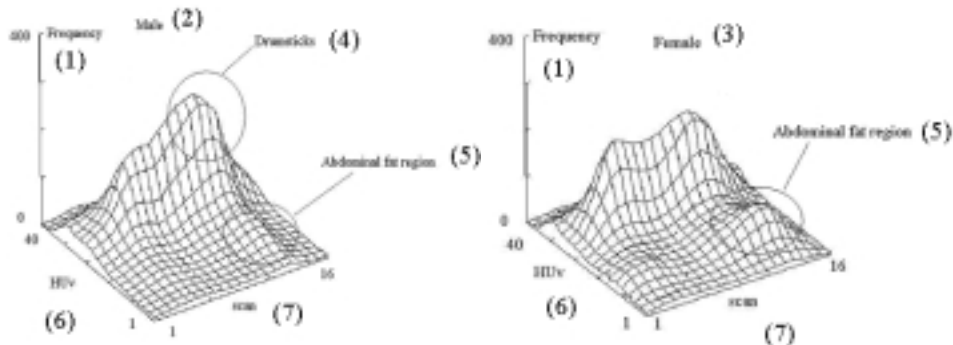
2. ábra: Hathetes korban készült 3D hisztogram hím,-és nőivarban

Gyakoriság(1), Hímivar(2), Nőivar(3), Combizomzat(4), Mellizomzat(5), Honsfield változók(6), Scan(7)

At 12 weeks of age, two marked differences can be seen between the two sexes (Figure 3). Besides to a same extent of the breast and the thigh muscle deposition a higher abdominal fat (HUv 6-12) content appeared in the females and, at the same time, the larger muscle peck corresponding the thigh, is clearly visible while abdominal fat deposition remained on a low level in males.

Figure 3

3D histograms at the age of 12 weeks of the male and female chickens



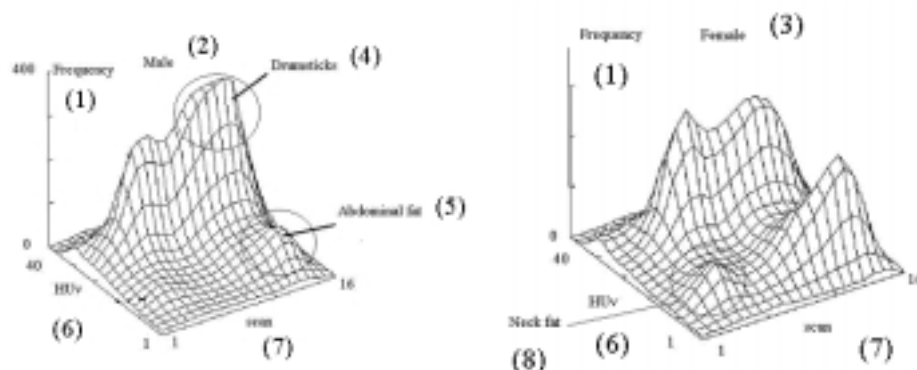
3. ábra: 12 hetes korban készült 3D hisztogram hím,-és nőivarban

Gyakoriság(1), Hímivar(2), Nőivar(3), Combizomzat(4), Abdominális zsír(5), Honsfield változók(6), Scan(7)

At the end, the last members of the series represent a 20-weeks-old category (*Figure 4*). Here, compared to previous categories, the amount of the fat increases significantly. The abdominal fat depot (12–16 scans) can especially be precisely identified, and the fatness of the neck part is quite significant, also in females. In addition, a large drumstick-thigh peak distinguished the males from females at this time.

Figure 4

3D histograms at the age of 18 weeks of the male and female chickens

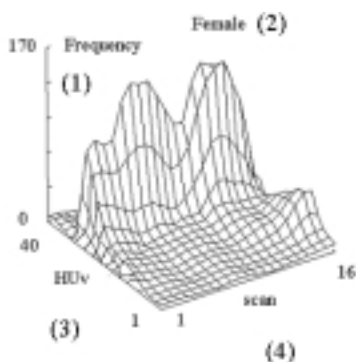


4. ábra: 18 hetes korban készült 3D hisztogram hím-, és nőivarban

Gyakoriság(1), Hímivar(2), Nőivar(3), Combizomzat(4), Abdominális zsír(5), Honsfield változók(6), Scan(7), Nyaki zsír(8)

Figure 5

3D histograms of changes of the body composition between 4 and 8 weeks of age of the female chickens



5. ábra: 4 és 8 hetes élethét közötti testösszetétel változás 3D hisztogramja nőivarban

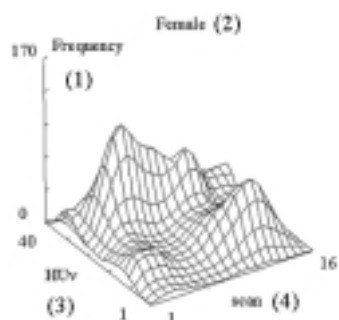
Gyakoriság(1), Nőivar(2), Honsfield változók(3), Scan(4)

Changes of the body composition within different ages were demonstrated with the differentiating of two 3D histograms demonstrating in female regarding to their pronouncedly larger fat tissue content. In *Figure 5* the change between 4 and 8 weeks is demonstrated. Confirmed of the above facts in the second phase of the broiler growth can be characterized by an intensive muscle development.

Besides the further breast muscle development intensive fat tissue deposition can be seen later especially in the abdominal fat region between 6 and 12 weeks of age (*Figure 6*). The neck fat deposition appeared also in this period which indicate the beginning of the further fat deposition in the whole body.

Figure 6

**3D histograms of changes of the body composition
between 6 and 12 weeks of age of the female chickens**

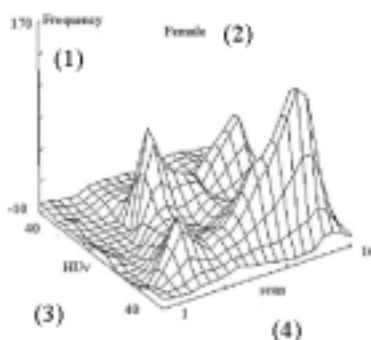


6. ábra: 6 és 12 hetes élethét közötti testösszetétel változás 3D hisztogramja nőivarban

Gyakoriság(1), Nőivar(2), Honsfield változók(3), Scan(4)

Figure 7

**3D histograms of changes of the body composition
between 12 and 18 weeks of age of the female chickens**



7. ábra: 12 és 18 hetes élethét közötti testösszetétel változás 3D hisztogramja nőivarban

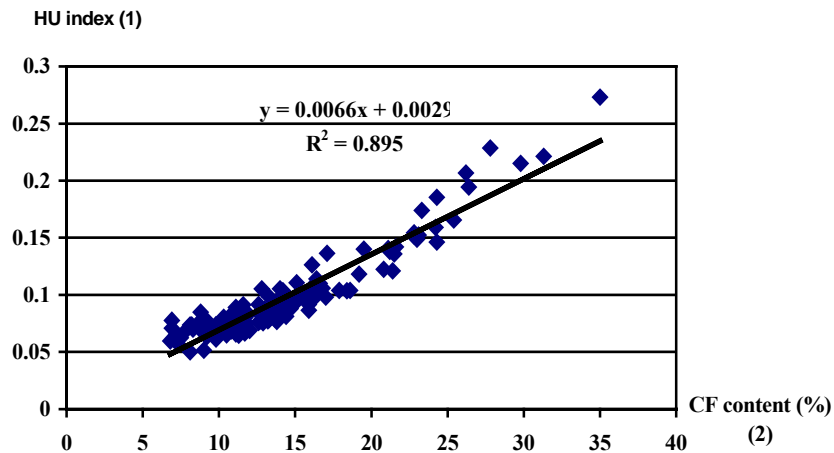
Gyakoriság(1), Nőivar(2), Honsfield változók(3), Scan(4)

Differences of the two histograms prepared between weeks 12 and 18 demonstrated that besides the decreased muscle tissue development, the fat tissue deposition became dominant in this growth phase, within the total body (Figure 7).

The fat content of the chicken body was first estimated with direct volumetry. There were no changes in the characteristic X-ray density values of muscle and fat tissues in the investigated live weight intervals. For this reason, in the CT images of broilers of different size, pixels with the same numeric value (HU value) indicate identical tissue types. Figure 8 shows the relationship between the CF content and the fat index, calculated from all the scans of the chickens ($R^2=0.895$, $P<0.05$).

Figure 8

Relationship between the HU index calculated from all images and the CF content



8. ábra: Az összes felvétel alapján számított HU index és a nyerszsír-tartalom közötti összefüggés vizsgálata

HU Index(1), Nyerszsír-tartalom(%) (2)

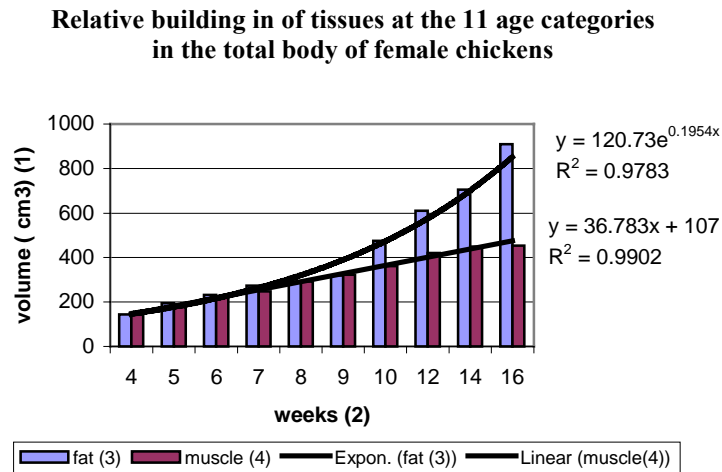
Figure 9 demonstrates the relative building in of both muscle and fat tissues in the total body (6-6 broilers in each group). The base (100%) is the tissue's volume of chickens of 4 weeks.

Three age categories were characterized by means of serial-scan based 3D histograms, during the 18-week raising period. The muscle development of males clearly exceeded that of females, at every age investigated. This was matched with a stronger abdominal fat deposition in females. The histograms, created from the tissue-specific density distributions, when compared to the results of the experimental slaughtering, proved to be suitable for the investigation of tissue development at pre-defined anatomical locations.

Altogether 10-15 minutes are needed for the simultaneous whole-body scanning of three chickens. The 3D histograms developed clearly show the tissue composition of chicken bodies, with separate peaks corresponding to the breast- or thigh region. Based on the 3D surfaces, the fat deposition differences can be analyzed in the two sexes. In a

similar manner, comparative investigations of the body composition were carried out on large bodied BUT and bronze type turkeys (Andrássy *et al.*, 2003).

Figure 9



9. ábra: A teljes test relatív szövetbeépülésének vizsgálata nőivarban

Térfogat(cm³)(1), Élethét(2), Zsír(3), Izom(4), Lineáris (izom)(4), Exponenciális (zsír)(3)

The fat indices being independent of live weight seem to be applicable in the prediction of whole body crude fat content. Former experiments also proved the applicability of these index values, as the results strongly correlated with the crude fat content of the animal (Romvári *et al.*, 2002). As the practical limit of this index is by 10% CF, and the chicken body contained the same fat amount over 4 weeks of age, the method worked well.

The correlations between the results of chemical analysis and pixel density data were strong enough for further development of prediction equations.

This methodology worked very well in case of fat content prediction, however, no adequate model could be achieved for protein (Bentsen and Sehested (1989), Svihus and Katle (1993) and Romvári *et al.* (1994) in chickens and also in other species (Romvári *et al.*, 1998; Romvári *et al.*, 2002)). In the authors opinion the applied method can effectively substitute the direct chemical analysis, especially as it is suitable for *non invasive* serial measurements of the same animal.

Fat content is one of the crucial quality traits also in broiler breeding. The good heritability of abdominal fat content ($h^2=0.40, 0.53, 0.56$ according to Leenstra, 1988; Wang *et al.*, 1991; Le Bihan-Duval, 1998) is a proper basis for the effective selection to lower it. The total body CF content investigated in the current study has a 0,53 h^2 value according to Horn (1981). Furthermore, the strong relationship between the abdominal and total body fat content is also known (Maurus *et al.*, 1988). Based on the above-mentioned facts it would be worth expanding this *non invasive* method into selection procedures of broiler breeding.

REFERENCES

- Andrássy, G., Romvári, R., Sütő Z., Szabó A., Horn, P. (2003). Comparative study of the body composition of different turkey genotypes by means of CT. Arch. Tierz., (accepted)
- Ballay A., Horn P., Kakuk T., Jeroch H., Beker J., Sütő Z. (1983). Nagytüstű pecsenyecsirkék (roasterek) előállításának biológiai, Technológiai és ökonómiai kérdései. Szaktanácsok. 4. 16-21.
- Bentsen, H.B., Sehested, E. (1989). Computerized tomography of chickens. Br. Poultry Sci., 30. 575-585.
- Grey, T.C., Robinson, D., Jones, J.M. (1982). Effect of age and sex on the eviscerated yield, muscle and edible offal of a commercial broiler strain. Br. Poultry Sci., 23. 289-298.
- Hancock, C.E., Bradford, G.C., Emmans, G.C., Gous, R.M. (1995). The evaluation of the growth parameters of six strains of commercial broiler chickens. Br. Poultry Sci., 36. 247-264.
- Havenstein, G.B., Ferket, P.R. (2002). Estimated genetic changes in broiler growth, feed conversion and yield, 1991-2001. 11th European Poultry Conference, Bremen All abstracts with the full paper included CD of the 11th EPC.
- Horn P., Sütő Z., Sørensen, P. (1998). Growth, feed conversion and mortality of commercial meat type chicken during a twenty week growing period. Arc.-f.-Geflügelkunde, 62. 16-20.
- Horn P. (1981). Handbook of poultry breeders. (In Hungarian) Mezőgazdasági Könyvkiadó, Budapest. 697.
- Le Bihan-Duval, E., Berri, C., Baeza, E., Millet, N., Beaumont, C. (2001). Estimation of the genetic parameters of meat characteristics and of their genetic correlations with growth and body composition in an experimental broiler line. Poult. Sci., 80. 839-843.
- Leenstra, F.R., Vereijken, P.F.G., Pit, R. (1986). Fat deposition in a broiler sire strain. I Phenotypic and genetic variation in and correlations between abdominal fat, body weight and feed conversion. Poultry Science, 65. 1225-1235.
- Leenstra, F.R., Pit, R. (1988). Fat deposition in a broiler sire strain. 3. Heritability of and genetic correlations among body weight, abdominal fat and feed conversion. Poult. Sci., 67. 1-9.
- Maurus, E.M., Kirchgeßner, M., Roth, F.X. (1988). Beziehungen Zwischen Teilstückanalysen und der Ganzkörperzusammensetzung bei Broilern. Arch.f. Geflügelkunde, 52. 261-267.
- Mitchell, A.D., Rosebrough, R.W., Conway, J.M. (1997). Body composition analysis of energy x-ray absorptiometry. Poult. Sci., 76. 1746-1752.
- Romvári R., Perényi M., Horn P. (1994). In vivo measurement of total body fat content of broiler chickens by X-ray computerised tomography. Znan. Prak. Poljopr. Tehnol., 24. 215-220.
- Romvári R., Szendrő Zs., Jensen, J.F., Sørensen, P., Milisits G., Bogner P., Horn P., Csapó J. (1998). Noninvasive measurement of body composition of two rabbit populations between 6 - 16 week of age by computer tomography. J. of Animal Breeding and Genetics, 11. 5383-395.
- Romvári R., Andrássy- Baka G., Repa I.; Závoda F., Sütő Z., Horn P. (2000). In vivo 3D evaluation of breast muscle of broiler chickens by means computer tomograph XXI World's Poultry congress Montreal, august 20-24 Proceedings CD 11-14.

- Romvári R., Hancz Cs., Petrási Zs., Molnár T., Horn P. (2002). Non-invasive measurement of fillet composition of four freshwater fish species by computer tomography. *Aqualture International*, 10. 231-240.
- Sørensen, P., Ducro, J.B. (1995). Age related and proportional aspects of growth in broilers. *Arc. f. Geflügelkunde*, No.Sonderheft, 30-34.
- Savory, C.J. (2002). Effects of long- term selection for broiler traits. 11. European Poultry Conference, Bremen All abstracts with the full paper included CD of the 11th EPC.
- Sütő Z., Horn P., Sørensen, P., Csapó J. (1998). Carcass trait, abdominal fat deposition and chemical composition of commercial meat type chicken during a twenty week growing period. *Arc.f.-Geflugelkunde*, 62. 21-25.
- Svihus, B., Katle, J. (1993). Computerised tomography as a tool to predict composition traits in broilers. Comparisons of results across samples and years. *Acta Agriculturae Scandinavia. Section A, Animal Science*, 43. 214-218.
- Wang, L., Chambers, J.R., McMillan, I. (1991). Heritabilities of adjusted and unadjusted feed and abdominal fat traits in a broiler dam population. *Poult. Sci.*, 70. 440-446.

Corresponding author (*levelezési cím*):

Gabriella Baka

University of Kaposvár, Faculty of Animal Science
H-7400 Kaposvár, Guba Sándor u. 40.
Kaposvári Egyetem, Állattudományi Kar
H-7400 Kaposvár, Guba Sándor u. 40.
Tel.: 36-82-314-155, Fax: 36-82-320-175
e-mail: baka.gabriella@sic.hu